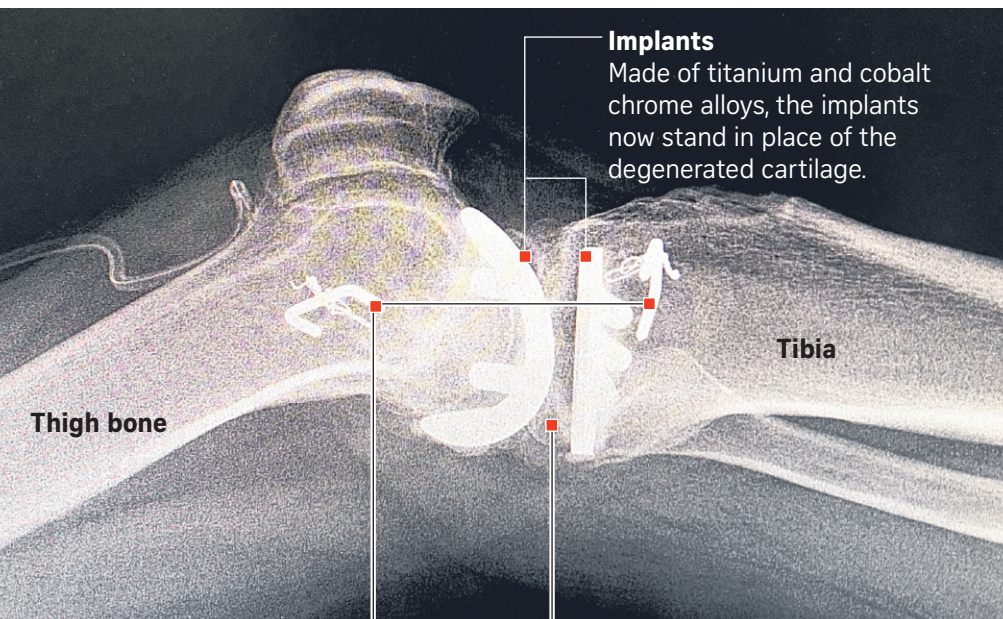


Mr Philip Muthiah's knee after partial knee replacement surgery

The X-ray shows evidence of his first ACL reconstruction surgery 25 years ago as well as where his early osteoarthritis developed subsequently and where the implants of his partial knee replacement have been inserted via makoplasty.



Thigh bone

Implants

Made of titanium and cobalt chrome alloys, the implants now stand in place of the degenerated cartilage.

Tibia

Staples in the knee

These are from the initial ACL reconstruction surgery 25 years ago

Knee joint

The surgery was performed in the interior right knee. Cartilage between the two bones at the knee joint had degenerated, causing the bones to rub together.